

Echocardiography Diagnostic Accuracy													
Measure Description: The proportion of potentially preventable and clinically important inaccurate diagnoses among congenital heart surgical patients.													
Numerator	Number of congenital heart surgeries with one or more clinically important inaccurate preoperative echocardiographic diagnoses ² (moderate clinical impact or greater ³) that are possibly preventable ⁴ or preventable ⁴ determined within 15 days after surgical procedure.												
Denominator	Number of congenital heart surgical patient who underwent preoperative echocardiography during the measurement period												
Denominator Exclusions	<ul style="list-style-type: none"> Non-primary cardiac operation preoperative echocardiograms (e.g. sternal closure or wire removal or cannulation/decannulation for extracorporeal support), preoperative studies performed from “outside” echocardiography laboratories. 												
Denominator Exceptions	None												
Definitions/Notes	<ol style="list-style-type: none"> Preoperative echocardiogram: The echocardiogram or echocardiography report that is primarily used for surgical planning or echocardiogram report that includes the complete anatomic elements used for surgical planning. Inaccurate Diagnoses: are defined as diagnoses that are unintentionally delayed, wrong or missed as judged from eventual appreciation of the existing data or of more definitive information. Clinical Impact <table border="1" style="width: 100%; border-collapse: collapse;"> <thead> <tr> <th style="text-align: center;">Clinical Impact</th> <th style="text-align: center;">Clinical Correlate</th> <th style="text-align: center;">Example</th> </tr> </thead> <tbody> <tr> <td style="text-align: center;">Minor</td> <td>No change in patient management or clinical course; no adverse outcome</td> <td>Undiagnosed left superior vena cava to intact coronary sinus discovered intra-operatively in patient undergoing surgery for patent ductus arteriosus ligation</td> </tr> <tr> <td style="text-align: center;">Moderate</td> <td>Alteration in patient management or clinical course without adverse patient event</td> <td>Undiagnosed patent ductus arteriosus but closed at surgery in patient undergoing ventricular septal defect closure</td> </tr> <tr> <td style="text-align: center;">Severe</td> <td>Adverse event contributing to patient injury; or error contributing to the performance of an unnecessary/additional invasive procedure; or error that contributed to patient demise</td> <td>Inaccurate diagnosis of atrial septal defect contributing to performance of unnecessary cardiac surgery; Missed diagnosis of anomalous origin of left coronary artery contributing to a myocardial infarction and death</td> </tr> </tbody> </table> Preventability 	Clinical Impact	Clinical Correlate	Example	Minor	No change in patient management or clinical course; no adverse outcome	Undiagnosed left superior vena cava to intact coronary sinus discovered intra-operatively in patient undergoing surgery for patent ductus arteriosus ligation	Moderate	Alteration in patient management or clinical course without adverse patient event	Undiagnosed patent ductus arteriosus but closed at surgery in patient undergoing ventricular septal defect closure	Severe	Adverse event contributing to patient injury; or error contributing to the performance of an unnecessary/additional invasive procedure; or error that contributed to patient demise	Inaccurate diagnosis of atrial septal defect contributing to performance of unnecessary cardiac surgery; Missed diagnosis of anomalous origin of left coronary artery contributing to a myocardial infarction and death
Clinical Impact	Clinical Correlate	Example											
Minor	No change in patient management or clinical course; no adverse outcome	Undiagnosed left superior vena cava to intact coronary sinus discovered intra-operatively in patient undergoing surgery for patent ductus arteriosus ligation											
Moderate	Alteration in patient management or clinical course without adverse patient event	Undiagnosed patent ductus arteriosus but closed at surgery in patient undergoing ventricular septal defect closure											
Severe	Adverse event contributing to patient injury; or error contributing to the performance of an unnecessary/additional invasive procedure; or error that contributed to patient demise	Inaccurate diagnosis of atrial septal defect contributing to performance of unnecessary cardiac surgery; Missed diagnosis of anomalous origin of left coronary artery contributing to a myocardial infarction and death											

	Preventability	Definition	Example
	Preventable	Error is preventable if accurate diagnosis is expected by the available images, imaging modality and/or imaging conditions (i.e. the diagnosis is readily apparent on study images but is not reported)	An echocardiogram image clearly demonstrates a patent ductus arteriosus by 2D and color Doppler but the study is interpreted as no patent ductus arteriosus
	Possibly preventable	Possibly preventable if an accurate diagnosis may be expected by echocardiography and/or imaging conditions but may have required a reasonably different technique such as complete anatomic sweep or use of color Doppler	Failing to diagnose an aortopulmonary window due to incomplete 2D and lack of color Doppler interrogation of the aorta and pulmonary artery
	Not preventable	Accurate diagnosis is not possible if the images, imaging modality, or imaging conditions do not permit diagnosis	“Failure” to image a ligamentum arteriosum contributing to a vascular ring or “failure” to diagnose coronary artery anomaly by transthoracic echocardiogram during active CPR
Measurement Period	Quarterly		
Sources of Data	<p>Preoperative echocardiographic findings/report will be compared to findings from other tests (e.g., cardiac catheterization, cardiac magnetic resonance imaging, cardiac computed tomography), operative observations, subsequent echocardiographic examinations, autopsy and outpatient clinic records up to 14 days* following the date of the cardiac surgery. Data regarding presence of diagnostic error, severity and contributors as learned from quality improvement meetings can be another source.</p> <p><i>*time frame can be limited to duration of admission</i></p> <p>The recommended optimal approach is that if an inaccurate diagnosis is determined to be present, the categorization of clinical impact (severity) and preventability will take place during each echocardiography laboratories’ quality meeting</p>		
Attribution	The echocardiography laboratory would collect, review, categorize and report their own data internally.		
Care Setting	Outpatient or inpatient		
Rationale			
Quality in diagnostic imaging is critically related to diagnostic accuracy.			

Inaccurate imaging findings may adversely impact patient safety and/or alter patient management.

Quality review is required of echocardiography laboratories for accreditation.

Patient risk factors for diagnostic error include weight < 5 Kg, moderate or complex anatomy, uncommon heart disease. Situational risk factors include echocardiograms performed and interpreted overnight and during weekends and unsedated children <36 months. Common anatomic features involved with diagnostic error include coronary arteries, aortic arch/branching and pulmonary veins.

Clinical Recommendation(s)

ACC/AHA guidelines

Spertus JA, et al; ACCF/AHA Task Force on Performance Measures. ACCF/AHA new insights into the methodology of performance measurement: a report of the American College of Cardiology Foundation/American Heart Association Task Force on performance measures. J Am Coll Cardiol. 2010 Nov 16;56(21):1767-82

Other guidelines:

Benavidez OJ, Gauvreau K, Jenkins KJ, Geva T. Diagnostic errors in pediatric echocardiography: development of taxonomy and identification of risk factors. Circulation. 2008 Jun 10;117(23):2995-3001

Stern KW, Gauvreau K, Geva T, Benavidez OJ. The impact of procedural sedation on diagnostic errors in pediatric echocardiography. J Am Soc Echocardiogr. 2014 Sep; 27(9):949-55.

Benavidez OJ, Gauvreau K, Geva T. Diagnostic errors in congenital echocardiography: importance of study conditions. J Am Soc Echocardiogr. 2014 Jun; 27(6):616-23.

Challenges to Implementation

1. Data collection and re-review of images requires time
2. Adjudication of discrepancy of imaging findings and other data will need to be fairly determined during QI meetings
3. This metric is not useful for centers that do not perform cardiac surgery

Authors

This metric development was an effort of the ACPC Section's Quality Metrics Work Group led by Leo Lopez, M.D., F.A.C.C. The College is grateful for the contributions of the following authors:

Oscar Benavidez, M.D.

Massachusetts General Hospital

Ann Kavanaugh-McHugh, M.D., F.A.C.C.

Vanderbilt Children's Hospital

John Kovalchin, M.D., F.A.C.C.

The Heart Center Nationwide Children's Hospital

Philip Spevak, M.D., F.A.C.C.

John's Hopkins Hospital

Leo Lopez, M.D, F.A.C.C.

Nicklaus Children's Hospital

Pei-Ni Jone, M.D., F.A.C.C.

Children's Hospital Colorado

Appendix: Case Review Process (Figure 1)

- This quality improvement activity will involve preoperative echocardiograms from patients presenting for congenital heart surgery.
- Data Collection Strategies
 - Full Review: 100% of cardiac surgical cases
 - Sample Review: 20 consecutive surgical cases with preoperative echocardiograms performed at the participating laboratory reviewed quarterly (100 cases annually)
- Surgical cases under review would be entered into a Non-Invasive Quality Improvement Database (NIQID) or spreadsheet (Figure 2)
- Secondary case review of the preoperative echocardiographic images for patients presenting for congenital heart surgery.
 - Staff cardiologists/cardiology fellows/trained sonographers from the echocardiography group will perform this review.
 - The preoperative echocardiographic findings will be compared to findings from other tests (e.g., cardiac catheterization, cardiac magnetic resonance imaging, and cardiac computed tomography), intraoperative observations, subsequent echocardiographic examinations, and autopsy and outpatient clinic records up to 15 days following the date of the cardiac surgery.
 - In many centers the preoperative echocardiograms undergo a secondary review prior to a child having cardiac surgery
- A case suspected of having an inaccurate diagnosis (candidate cases) would be identified and noted in the a Non-Invasive Quality Improvement Database or spreadsheet
- Among the candidate cases, the relevant clinical and image data related to the inaccurate diagnosis will be presented at a monthly Non-Invasive Quality Improvement Seminar
- A consensus based review of the case and the ensuing discussion will be used to finalize categorization of the inaccurate diagnosis type, severity, preventability and contributor. (Benavidez, et al. *Circulation* 2008)
- Surgical cases under review with a minimum dataset would be entered into a Non-Invasive Quality Improvement Database or spreadsheet
 - Minimal data set includes age, initial diagnosis, presence of diagnostic error, anatomic segment of diagnostic error, final diagnosis, clinical impact, preventability and primary contributor
 - The finalized categorization will be entered into NIQID
- Reporting Strategies
 - Diagnostic Error Rate: Total number of preoperative cases with clinically important, potentially preventable diagnostic errors over the total number of preoperative echocardiograms
 - Diagnostic Accuracy Rate: Total number of preoperative cases with accurate diagnoses over the total number of preoperative echocardiograms

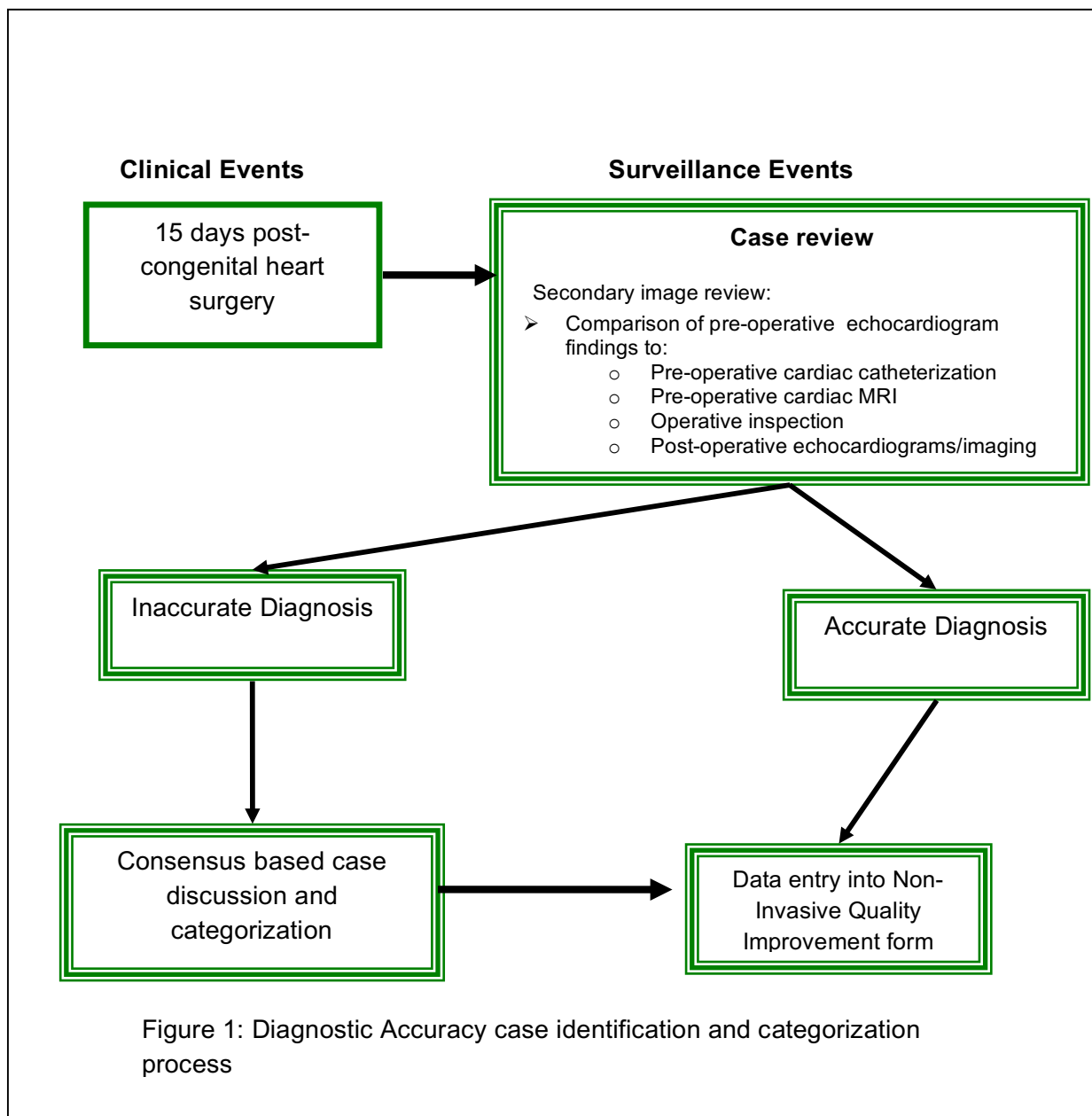


Figure 1: Diagnostic Accuracy case identification and categorization process

Figure 2. Example spreadsheet – minimal dataset

Patient	Age	Initial diagnosis	Accurate Diagnosis?	Final diagnosis	Method of discovery	Clinical impact	Preventability	Contributor
JJ1/1/2001	14 year	Normal	No	Coarctation	Review of echocardiogram	Moderate	Preventable	Mis-identification of study images
AB 2/2/2013	1 year	ASD secundum	No	ASD secundum and muscular VSD	Subsequent echocardiogram	Minor	Possibly preventable	Incomplete examination of the ventricular septum
DC 3/1/2010	4 years	ASD primum and cleft mitral valve	Yes	ASD primum and cleft mitral valve		--	--	--